

**PATIENT**

Pierre Kersey

**SPECIES**

Feline

**BREED**

DSH

**SEX**

Male Neutered

**AGE**

8 years

**WEIGHT**

9lbs

**INTERPRETED BY**

Maggie Machen Lamy,  
 DVM, DACVIM  
 (Cardiology)

**IMAGING PERFORMED BY**

Kathleen Byrnes

**HOSPITAL NAME**

Monroe Road Animal  
 Hospital

**REFERRING VET**

Dr. Widay

**INVOICE**

45824

**DATE**

11/19/25

**PRESENTING CLINICAL SIGNS**

History: Allergy issues and dermatitis; very itchy. Currently on Hydrolyzed diet. New murmur heard on exam. Assess prior to steroids.

**ECHOCARDIOGRAM FINDINGS**

2D, m-mode, color flow and doppler imaging is available. The left ventricular wall is mildly hypertrophied with a focal septal bulge. There is a diffusely hyperechoic endocardium consistent with fibrosis and ventricular remodeling. Mild papillary muscle hypertrophy. The right ventricle is subjectively normal in size and morphology. There is no left atrial enlargement present. No right atrial enlargement present. Mildly elevated RVOT velocity with a dynamic profile. There is no obvious systolic anterior motion (SAM) of the mitral valve present. LVOT velocity appears normal. There is no obvious mitral regurgitation present. No other obvious valvular regurgitation is present. There is no pericardial effusion noted. No pleural effusion appreciated.

**CARDIAC CHART**

FELINE CARDIAC PARAMETERS	BODY WEIGHT (kg)	HR (BPM)	IVSd (cm) <small>(Moise, Pipers)</small>	LVIDd (cm) <small>(Moise, Pipers)</small>	LVWd (cm) <small>(Moise, Pipers)</small>	FS (%)	EF (%)
NORMAL PARAMETER	-----	150-240	0.35-0.55	<2 (mean 1.5)	3.5-0.55	35-67	80-100
PATIENT	4.1	150	0.69	1.3	0.65	58	90
FELINE CARDIAC PARAMETERS	LA/AO <small>(Boon)</small>	LA/AO HEART BASE (Swe) <small>(Abbott)</small>	LA 2D short axis Base view (cm) <small>(Abbott)</small>		LVOT VEL <small>(m/s)</small>	RVOT VEL <small>(m/s)</small>	E max <small>(m/s)</small>
NORMAL	<1.5	<1.3	<1.2		<1.6	<1.3	<0.9
PATIENT	1.3	1.1	1.3		0.8	2.0	NM

*\*Note: All measurements based upon multi-modal images and methods. An average value is reported.  
 Adapted from June Boon, Veterinary Echocardiography, 1998  
 Abbott J & MacLean H JVIM 2006;20: 111-119, Moise et al. Am J Vet Res 47:1476, 1986. Pipers et al. Am J Vet Res 40:882, 1979.*

**INTERPRETATION OF THE FINDINGS & FURTHER RECOMMENDATIONS**

Hypertrophic cardiomyopathy (HCM) is a rule out diagnosis once a patient is deemed normotensive and euthyroid. Both should be considered in his case. Regardless, the left atrial dimension is normal in this study indicating the risk for clinical issues is low. Mild RVOT velocity elevation is noted, which is likely the origin of the murmur and is a benign finding (i.e. physiologic and not associated with pathology). No additional issues are identified.

No therapy is currently indicated. Atenolol may be recommended in the future should SAM be identified, and the hypertrophy/LA dimension worsen progress. It is important to note however that no medications have been shown to definitively alter long term outcome at this stage regardless.

Monitor at home for any respiratory issues or signs of blood clot events (neurologic change, paralysis, etc.). Anesthetic risk is considered mild, however judicious IV fluid rates are advised to avoid fluid overload. Additionally, drugs that stimulate heart rate should be avoided unless clinically necessary (glycopyrrolate, atropine).



**PATIENT**

Pierre Kersey

**SPECIES**

Feline

**BREED**

DSH

**SEX**

Male Neutered

**AGE**

8 years

**WEIGHT**

9lbs

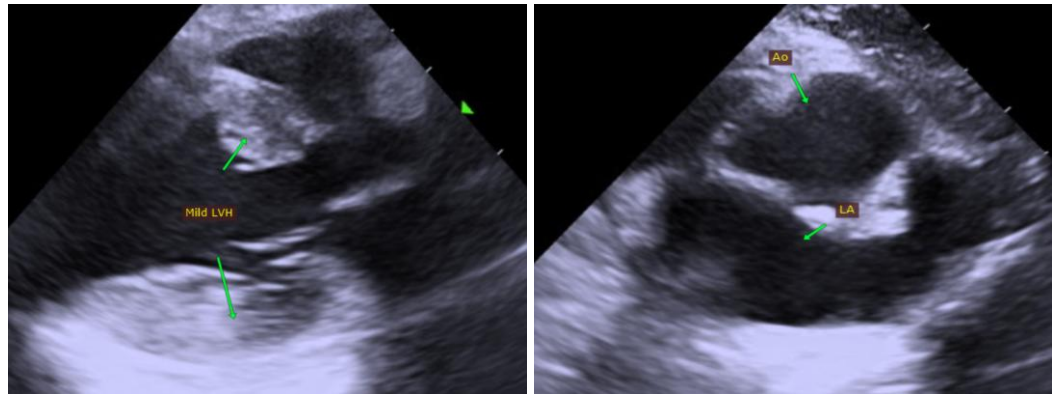
Risks for steroid use typically follows atrial dilation, which in this case is low. That being said, monitoring for any signs of acute intolerance, particularly during the initiation phase.

**PLAN**

A screening blood pressure and thyroid panel is recommended every 6-12 months.

A recheck echocardiogram is recommended in 6-12 months to assess for progression.

**IMAGES**



The information and recommendations provided are based on the images presented by the referring veterinarian. No evaluation can be communicated regarding pathology that was not visible in the image/video clips provided.

Thank you for this referral. This report was generated using transcription software, and minor dictation errors may be present. If the clinical or image interpretation does not parallel your findings or if I can be of any further assistance, please contact me.

**INTERPRETED BY**

Maggie Machen Lamy,  
DVM, DACVIM  
(Cardiology)

**IMAGING PERFORMED BY**

Kathleen Byrnes

**HOSPITAL NAME**

Monroe Road Animal  
Hospital

**REFERRING VET**

Dr. Widay

**INVOICE**

45824

**DATE**

11/19/25

Maggie Machen Lamy, DVM  
Diplomate of the American College of Veterinary Internal Medicine (Cardiology)  
info@sonopath.com